

**CLINICAL PROFILE OF CASES WITH LEIOMYOMA****Dedeepya Rambhakta,<sup>1</sup> \*N. Madhavi<sup>2</sup>**<sup>1</sup>Senior Resident, Dept. of OBG, Kamineni Institute of Medical Sciences, Narketpally<sup>2</sup>Professor, Dept. of OBG, Kamineni Institute of Medical Sciences, Narketpally**Abstract**

**Introduction:** Uterine leiomyomas are the most common benign tumours in women of reproductive age group. They are symptomatic in 50% of cases with peak incidence of symptoms in the 30s and 40s. Presentation is quite variable. Majority of fibroids are asymptomatic in the early stages and get less clinical attention due to undiagnosed disease, while symptomatic women complain of pain, abdominopelvic mass, abnormal uterine bleeding, mainly menorrhagia.

**Aims & Objectives:** To study the clinical manifestations of fibroid uterus.

**Materials & Methods:** This is a hospital based prospective study of 50 leiomyoma cases during a period of January 2017 to August 2018. After taking consent all cases were enrolled in the study and a detailed history of presenting complaints and associated symptoms were noted, along with menstrual history. A thorough general and systemic examination was performed. Examination assessed the presence or absence of mass on P/A, P/S, P/V examination. All cases underwent ultrasound to detect and know the position of leiomyoma, specimens were sent for histopathological examination and analysed.

**Results:** Majority of women were in between the age group of 36-45 years. Majority of women were parous (92%). Most common presenting symptom among the fibroid cases was menstrual irregularity (86%), Followed by lump in abdomen (50%), Pain was reported in 40% of patients. Among the patients with menstrual disturbances, menorrhagia, dysmenorrhea, polymenorrhea were common. Cases of fibroid that had a palpable mass were firm in consistency and mobile.

**Conclusion:** Thus we conclude that menstrual irregularity was most common presenting symptom, followed by lump in abdomen and pain abdomen. Menorrhagia, dysmenorrhea, polymenorrhea were most common type of menstrual abnormality.

**Corresponding Author:**

N. Madhavi  
Professor and HOD of OBG,  
Department of OBG,  
Kamineni Institute of Medical  
Sciences, Narketpally, Nalgonda,  
Telangana State - 508254  
Email Id: adhavinacharaju@yahoo.in

**Introduction:**

Fibroids have therapeutic, diagnostic, and psychological challenges, being the most commonest benign tumour of the uterus,<sup>1</sup> It is essential to analyze its clinical manifestations in various perspectives. They are slow growing, monoclonal

tumours, of smooth muscle cells of myometrium.<sup>2</sup> They are composed of large amount of extra cellular matrix containing collagen, fibronectin, proteoglycan. Fibroid can be single or multiple in number. Fibroids are symptomatic in 50% of the cases, with peak incidence of symptoms in 30s or 40s. Symptoms depend on site and size. Studies have shown that women with myomas are more likely to present with menorrhagia, abdominopelvic mass<sup>3-9</sup> but may also present with dyspareunia, dysmenorrhea, abdominal discomfort, or bloating, painful defecation, backache, urinary frequency, or retention, and infertility.<sup>5-9</sup> During pregnancy, fibroids may cause miscarriage, bleeding, abnormal lie and presentation. Commoner symptoms include abdominal mass, menorrhagia, pain, dysmenorrhea and pressure symptoms from myoma.

### **Aims and Objectives:**

To study the clinical manifestations of fibroid uterus.

### **Materials & Methods:**

**Study Design:** Prospective observational study

**Study Sample:** 50

**Place Of Study:** Kamineni Institute of Medical Sciences.

### **Inclusion Criteria:**

1. Patient attending gynecological OPD who have abnormal uterine bleeding, abdominal lump or any other symptoms of fibroid who have been detected to have fibroid by ultrasonography.

2. Age group 20-60 years.
3. Patient undergoing hysterectomy or myomectomy for fibroid uterus.
4. Patient willing to give consent for enrolment in the study.

### **Exclusion Criteria:**

1. Patients age <20 and >60 years.
2. Patients with intrauterine pregnancy.
3. Patients having other pelvic pathologies.

### **Methodology:**

Selected patients were informed about the study, written consent was taken and then enrolled into the study. Clinical presentation was studied by taking detailed menstrual, medical, personal and family history in a specifically designed proforma. Patients were subjected to investigations like ultrasonography scan to confirm the presence and location of fibroid, surgical profile. Patients were managed with appropriate management according to standard hospital protocol. Post-surgery the hysterectomy/ myomectomy specimens were sent for histopathological examination and leiomyoma confirmed.

### **Results:**

**Age-In** the present study all the patients were in the range of 20-60 years. Maximum numbers of patients were in the age group of 36-45 years, accounting for (76%) of all the cases.

**Table 1 - Age group distribution (n=50)**

Age groups	No. of patients	%
Upto 25	1	2%
26-35	4	8%
36-45	38	76%
46-55	6	12%

>55	1	2%
-----	---	----

**Parity:** (8%) of the cases are nullipara, 11 (22%) of them are para 1, 21 (42%) of them are para 2, 14(14%)of them are para 3 or more. Therefore, most of them were parous (92%).

**Table 2 - Parity (n=50)**

Parity	No. of patients	%
Nullipara	4	8%
Para 1	11	22%
Para 2	21	42%
Para >/=3	14	28%

**Clinical manifestations** – majority (86%) had menstrual irregularities, 50% had lump abdomen, 40% had pain abdomen, and 22% had urinary complaints.

**Table 3 - Clinical manifestation (n=50)**

Clinical manifestations	No. of patients	%
Menstrual Symptoms	43	86%
Pain Abdomen	20	40%
Mass Per Abdomen	25	50%
Urinary Symptoms	11	22%

**Menstrual symptoms-** Menorrhagia (60%), dysmenorrheal (42%), polymenorrhea (24%) were most common type of menstrual abnormality.

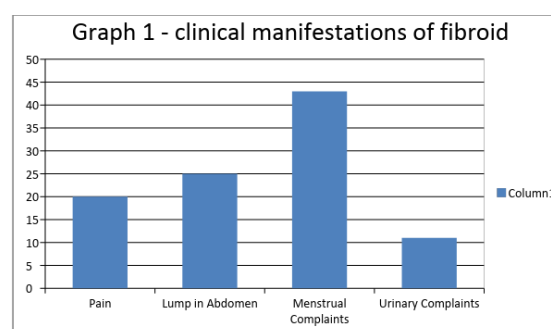
### Discussion:

The present study was conducted in the Department of Obstetrics and Gynecology with objectives to study the clinical manifestations of fibroid uterus. In the present study a total of 50 cases manifested with the symptoms of fibroid

**Table 4-Menstrual Symptoms**

Menstrual Symptoms	No. of Patients	%
Menorrhagia	30	60%
Dysmenorrhoea	21	42%
Polymenorrhoea	12	24%
Metrorrhagia	1	2%
Oligomenorrhoea	0	0%

**Graph 1 - Menstrual symptoms**



were studied from January 2017 till august 2018. Histopathological examinations were conducted for confirmation of fibroid uterus.

Out of the 50 cases studied, it was observed that majority of women were in the age group of 36-45 years. Thus fibroid cases were common in 3<sup>rd</sup> and 4<sup>th</sup> decade of life and majority of women were parous (92 %), the findings are comparable to Pradhan et al<sup>10</sup> where mean age was 43.4 years, and 90% were parous and Okogbo et al<sup>11</sup> where mean age was 39.4 years and 68% parous. The most common presenting symptom was menstrual irregularity (86%) followed by lump in abdomen (50%), pain abdomen (40%), urinary complaints were reported in (22%) of cases. Results are similar to pradhan's study<sup>11</sup> where patients reported menstrual disturbance (73%) pain abdomen (58.4%), lump abdomen (13%) , urinary complaints (2.2%) and okogbo's study<sup>4</sup> also showed similar results where menstrual irregularities (47.7%), abdominal lump (39%), pain (24%) were chief complaints.

Present study found that menorrhagia as principle menstrual irregularity (60%) followed by dysmenorrhoea (42%) and polymenorrhoea (24%). Similar presentation was reported at pradhan where menorrhagia is 73% dysmenorrhoea 18%, okogbo<sup>12</sup> and jose alberto fonseca-moutiqwnho et.al.<sup>13</sup> On clinical examination, out of 50 cases of fibroid, 25 had a palpable mass.

Fibroids are generally associated with increased risk of heavy or prolonged menstrual flow.<sup>14,15</sup> Proposed reasons for this include increase in endometrial surface area, distortion and congestion of surrounding vessels, abnormal endometrial development, increase in blood flow to the uterus, and poor contractility.<sup>16,17</sup>

### Conclusion:

Thus we conclude from this study that menstrual irregularity was most common presenting symptom, followed by lump in abdomen and pain abdomen. Menorrhagia, dysmenorrhea, polymenorrhea were most common type of menstrual abnormality.

### References:

1. Nilo Bozini, Edmund C Baracat, The History Of Myomectomy At The Medical School Of University Of São Paulo, Clinics 2007; 62(3):209-10.
2. William H. Parker, Etiology, Symptomatology, And Diagnosis Of Uterine Myomas, Fertility And Sterility 2007 April; 87(4). Doi:10.1016/J.Fertnstert.2007.01.093.
3. Ezeama C, Ikechebelu J, Obiechina N, Ezeama N: Clinical Presentation of Uterine Fibroids in Nnewi, Nigeria: A 5year Review. Ann Med Health Sci Res 2012; 2:114-118.
4. Okogbo FO, Ezechi OC, Loto OM, Ezeobi PM: Uterine Leiomyomata in South Western Nigeria: a clinical study of presentations and management outcome. Afr Health Sci 2011; 11:271-278.
5. Aboyeji AP, Ijaiya MA: Uterine fibroids: a ten year clinical review in Ilorin, Nigeria. Niger J Med 2002;11:16-19.
6. Okezie O, Ezegwui HU: Management of uterine fibroids in Enugu, Nigeria. J Obst Gynaecol 2006;26:363-365.
7. Sankaran, S.; Manyonda, I. "Medical management of fibroids". Best Practice & Research Clinical Obstetrics & Gynaecology 2008; 22(4):655.
8. Ozumba BC, Megafu UC, Igwegbe AO: Uterine fibroids: clinical presentation and management in a Nigerian teaching hospital. Ir Med J 1992; 85:158-159.
9. Emembolu JO: Uterine fibromyomata: presentation and management in northern Nigeria. Int J Gynaecol Obstet 1987;25:413-416.
10. Pramila Pradhan, Nitish Acharya, Binit Kharel, Manoj Manjin, Uterine Myoma: A Profile of Nepalese women, N. J. Obstet. Gynaecol. 2006; 1(2):47-50.
11. José Alberto Fonseca Moutinho et al, Abnormal uterine bleeding as a presenting symptom is related to multiple uterine leiomyoma: an ultrasound based study, International Journal of Women's Health 2013;5:689-69.
12. Akinyemi BO. Adewoye BR. Fakoya TA. Uterine fibroids. A review. Niger J Med 2004; 13:318-29.
13. Chen CR, Buck GM, Courey NG, Perez KM, Wactawski Wende J. Risk factors for uterine fibroids among women undergoing tubal sterilisation. Am J Epidemiol 2001; 153:20-6.
14. Payson M, Leppert P, Segar J. Epidemiology of myomas. Obstet Gynecol Clin North Am 2006; 33:111.

15. Marinho JL, Eskenazi B, Warner M, Samuels S, Vercellini P, Gavoni N, et al. Uterine leiomyoma and menstrual cycle characteristics in a population based cohort study. *Hum Reprod* 2004; 19:2350-5.
16. Cantuaria Gh, Angioli R, Frost L, Duncan R, Penalver Ma. Comparison Of Bimanual Examination With Ultrasound Examination Before Hysterectomy For Uterine Leiomyoma. *Obstet Gynecol* 1998; 92:109-12.
17. Aydin C, Eri<sup>o</sup> S, Yalçin Y, Sen Selim H, A giant cystic leiomyoma mimicking an ovarian malignancy, nt *J Surg Case Rep*. 2013; 4(11):1010-2
18. Wallach EE, Vlahos NF, Uterine Myomas: An Overview Of Development, Clinical Features, And Management, *Obstet Gynecol*. 2004 Aug; 104(2):393-406.
19. Wise LA, Palmer JR, Stewart EA, Rosenberg L. Age†specific incidence rates for self reported uterine leiomyomata in the black women's health study. *Obstet Gynecol* 2005; 105:563-8.
20. DeWaay DJ, Syrop CH, Nygaard IE, Davis WA, Van Voorhis BJ. Natural history of uterine polyps and leiomyomata. *Obstet Gynecol* 2002; 100:3-7.