

An approach to histopathology-based diagnosis and treatment of Mycetoma foot

*Arun Kumar M¹, Imran Kazmi², Madhukar N³, Akhila Reddy E³, Sheshagiri Rao T⁴

¹Professor and Head, ²Assistant professor, ³ Post Graduates, Department of Dermatology and Venereology, ⁴Professor, Department of Pathology, Kamineni Institute of Medical Sciences, Narketpally, Nalgonda District, Telangana State, India.

ABSTRACT

Mycetoma is a localized chronic infection caused by various species of fungi or actinomycetes, and characterized by the formation of aggregates of the causative organisms (grains) within abscesses and clinically characterized by asymptomatic swelling, multiple discharging sinuses with grains. Culture and histopathology is the mainstay for diagnosis. Treatment depends on the type of organism. We are presenting one classical case of Madura foot.

Key words: Actinomycetoma, Granules, Splendore Hoeppli material

Introduction:

Madura foot is a deep mycosis commonly seen in agricultural workers and in individuals who walk on barefoot. It is caused by two groups of organisms, bacteria belonging to the group of Actinomycetes and the true fungi named eumycetes.¹ The case presented here is from the rural part of India; agricultural worker presenting with induration, minimal discharge from sinuses, and fibrosis over the foot for the last 3 years. Differentiation between the two mycetomas is important as the two etiologic agents have a different course of disease progression and treatment.²

As even multiple cultures can provide no growth at times, culture-negative cases can be diagnosed and common species can be identified on histopathology if a careful stepwise approach is followed.³ Actinomycetomas were treated with a favourable outcome without any relapse whereas eumycetomas had frequent relapses.

Case report

A 45 year old female patient, presented to outpatient

department of dermatology and venereology (DVL) with asymptomatic swelling of left foot with multiple solid elevated lesions containing openings discharging grain like material since 1 year. Initially, she developed a single swelling on the inner aspect of the left foot, the size of which gradually increased and similar new swellings appeared over a period of next 3 months. Then, the patient noticed openings in the lesions discharging white rice grain like material from a few lesions. Then most of the lesions started to discharge the grain like material with pus. The patient gave history of blunt trauma over the foot while working barefoot in the field, one year back. There was history of fever on and off since 1 month. No history of cough with sputum or chest pain. There was no history of pain or itching over the lesions. No history of associated bone or joint pains. There was no history of difficulty in walking and limb movements.

Cutaneous examination revealed indurated swelling of left foot extending medially from medial malleolus, instep of foot, medial half of dorsum of foot and dorsum of 1st & 2nd metatarsals and encroaching just above the medial half of ankle joint. There was no local rise of temperature and tenderness. There were multiple nodules with sinuses draining sero-purulent discharge over medial aspect of left foot (Fig.1). Skin over the swelling was not pinchable. All routine blood examination and biochemical parameters were normal.

*Corresponding Author :

Arun Kumar M,
Professor & Head,
Department of Dermatology and Venereology,
Kamineni Institute of Medical Sciences, Narketpally,
Nalgonda district, Telangana State, India - 508254
drmettaarun@yahoo.co.in

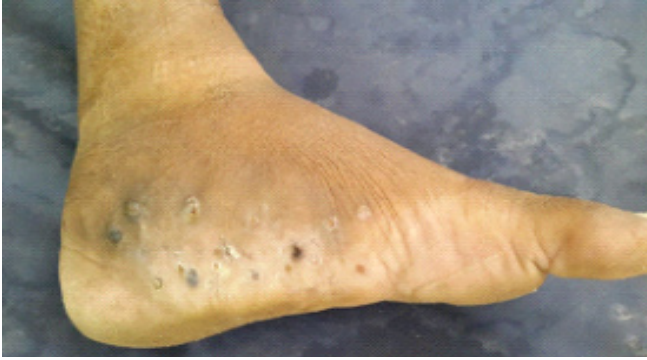

Fig.1: Picture shows multiple nodules with sinuses draining seropurulent discharge over medial aspect of left foot

On local examination, pus discharge showed pale coloured grains. Grams stain-smear showed many pus cells and gram positive bacilli with branching filaments. Culture of bacteria and fungus showed no growth after 15 days of incubation. Histopathology showed aggregates of granules which were admixed with hyalinised amorphous material with peripheral radiating club like projections (Splendore-Hoeppli material). These granules were surrounded by inflammatory infiltrate composed predominantly of neutrophils and also eosinophils, lymphocytes, plasma cells and epithelioid macrophages (Fig 2). X-ray showed soft tissue swelling on medial aspect of left foot and evidence of lucencies in shaft of 1st & 2nd metatarsals with mild expansion of shaft of 2nd metatarsal (actinomycetoma).

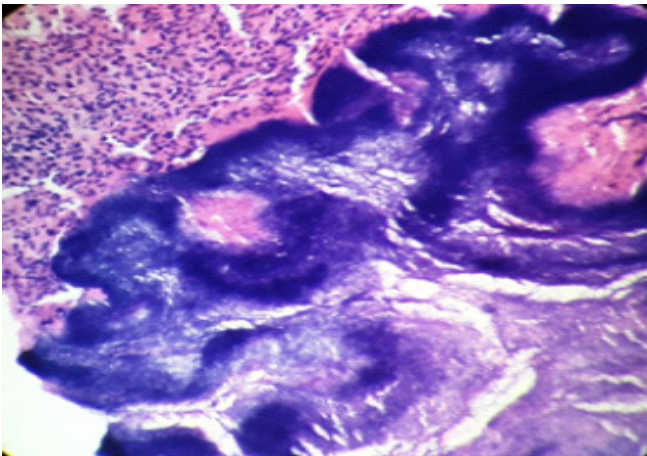


Fig 2: Histopathology showed aggregates of granules with hyalinised amorphous material with peripheral radiating club like projections (Splendore-Hoeppli material)

Based on history, cutaneous examination, histopathology and immunofluorescence study, diagnosis of actinomycetoma was confirmed. Patient was started on Welsh regimen: Injection Amikacin 375 mg (15 mg/kg) twice daily and Tablet Cotrimoxazole DS (160/800 mg) twice daily for 21 days followed by Tab. Cotrimoxazole DS twice daily for 15 days. Two such cycles were instituted. Patient responded very well to the medication and was on regular follow up (Fig. 3).

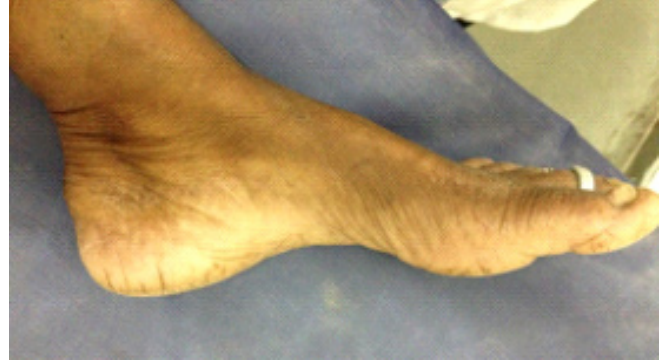

Fig 3: Treatment response after two cycles of Welsh regimen

Discussion

Madura foot is a deep mycosis caused by eumycetes (fungi) and actinomycetes (filamentous bacteria). It is seen in tropical and subtropical regions. The disease was first recognized by Dr Gill in 1842 from South India.⁴ Eumycotic mycetomas were more common in northern India; however, the recent trend shows an increase in incidence of Actinomycetoma.

Common Actinomycotic agents are Actinomadura, Streptomyces and Nocardia, whereas common eumycotic agents are Madurella, Pseudallescheria, Acremonium and Leptosphaeria.¹ This disease is defined by a triad of tumefaction of the affected tissues, formation of multiple draining sinuses and the presence of grains.⁵ Its clinical manifestation though varied may be characterized by numerous discharging sinuses containing color specific granules depending on the causative fungi.^{4, 6}

Madura foot is confirmed histologically or by culture studies. Features which help to differentiate eumycetoma and actinomycetoma include the following : firstly, colour of grains, that is, if grains are

black or colourless, it is eumycetoma, while if they are white or red it is actinomycetoma. Secondly, cutaneous lesions are more inflammatory, destructive and rapidly progressive in patients with actinomycetoma, while cutaneous lesions are slowly progressive and encapsulated for a long time in eumycetoma. Thirdly, radiologically eumycetoma presents as few, larger (>1 cm in diameter) lytic lesions, whereas multiple, smaller lytic lesions are seen in actinomycetoma.

The diagnosis of eumycetoma is made provisionally clinically when discharging grains are visible to the naked eye.⁷ The grains vary in color, size and consistency depending on the causative agent and can be confirmed by culture method. Cultures of mycetoma are usually problematic due to stringent growth requirements, contamination by other bacterial organisms and because patients usually present late when the fibrosis predominates over the purulent discharge. Thus repeated attempts to culture the microorganism can fail.⁷ The grains of actinomycetoma appear homogeneously eosinophilic, while these appear blue in the centre with pink filaments on the periphery on staining (SPLENDORE-HOEPLLI material). Its diagnosis could be difficult in the absence of discharging sinuses, but can be achieved with a combination of clinical features, granular examination, histopathological, immunohistochemical, and radiological studies. Actinomycetoma shows response to a wide range of antibiotics including Aminoglycosides, Rifampicin, Dapsone, Sulfadoxine-pyrimethamine, Amoxicillin-Clavulanic acid, Doxycycline and Cotrimoxazole.^{8,1}

As various studies have already shown that it is much better to use combination of drugs to treat mycetoma rather than relying on single drug to avoid resistance, increasing response and decreasing duration of treatment. There are some well-established regimens like Ramam¹ and Welsh⁸ regimens to guide about duration of treatment and combination of drugs. These regimens were based on above principle and show high efficacy and are followed by many clinicians to treat actinomycetoma.⁸

References

1. Ramam M, Bhat R, Garg T et al. A modified two-step treatment for actinomycetoma. *Indian J Dermatol Venereol Leprol* 2007;73:235–39.
2. Kaliswaran AV, Sentamilselvi G, Janaki C, Janaki VR. Therapeutic response in mycetoma: A study of different regimens. *Indian J Dermatol* 2013;48:154-59.
3. Sanjay Singh Chufal, Naveen Chandra Thapliyal, Manoj Kumar Gupta. An approach to histology-based diagnosis and treatment of Madura foot *J Infect Dev Ctries* 2012;6:684-88
4. Beniwal NS, Arora S, Baveja S, Sood A, Mehta R, Bal AS. Coexistent Actinomycosis and Eumycetoma in an Immunocompetent Patient. *Indian Journal of Dermatology* 2014;59:413-14.
5. Butas CA, Read SE, Coleman RE, Abramovitch H. Disseminated actinomycosis. *Can Med Assoc J* 1970;103:1069-71.
6. Gabhane SK, Gangane N, Anshu. Cytodiagnosis of eumycotic mycotoma: a case report. *Acta Cytol* 2008;52:354-56.
7. Hag IA, Fahal AH, Gasim ET. Fine needle aspiration cytology of mycetoma. *Acta Cytol* 1996;40:461-64.
8. U.S. Agarwal, R.K. Besarwal, R. Gupta, P. Agarwal. Treatment of actinomycetoma foot – our experience with ten patients. *J EADV* 2013;27:1505-13.